International Journal of Science and Research Archive
eISSN: 2582-8185
Cross Ref DOI: 10.30574/ijsra
Journal homepage: https://ijsra.net/

(RESEARCH ARTICLE)

Check for updates

ANTROCHOANAL (KILLIAN) POLYPS: EXPERIENCE OF THE AVICENNE MILITARY HOSPITAL OF MARRAKECH: A SERIES OF 34 CASES

Sara Addi *, Mossab Tayane, Sara Aourarh, Taoufik Ouail El Assead, Ilias Benchafai, Abdelfattah Aljalil, Youssef Darouassi and Mohamed Mliha Touati.

Department of Otorhinolaryngology and Head and Neck Surgery, Avicenne Military Hospital, Marrakech, Morocco.
* Corresponding Author

International Journal of Science and Research Archive, 2026, 21(02), 513–520

Publication history: Received on 02 October 2026; revised on 11 November 2026; accepted on 13 November 2026

Article DOI: https://doi.org/10.30574/ijsra.2026.21.2.1996

Copyright © 2026 Author(s) retain the copyright of this article. This article is published under the terms of the Creative Commons Attribution License 4.0

ABSTRACT

Objectives: To describe the epidemiological, clinical, radiological, histological, therapeutic and outcome features of antrochoanal polyp (ACP).

Material and methods: Retrospective, study conducted in the ENT department of the Avicenne Military Hospital of Marrakech, including all patients operated on for ACP between January 2020 and December 2025. Epidemiological, clinical, endoscopic, CT, histopathological and outcome data were collected on a standardised form and analysed using descriptive statistics.

Results: Thirty-four patients were included. Mean age was 35.4 years (range: 12–82), with a peak between 30 and 40 years and more than 65% of patients under 40. The male-to-female ratio was 1.83 (22 men, 12 women). Mean time to consultation was 3.91 years (1 month – 30 years). Nasal obstruction was constant (100%), unilateral in 94.1% of cases; rhinorrhoea was present in 26 patients (76.47%), headache in 5 (14.70%), epistaxis in 3 (8.82%) and nocturnal snoring in 4 (11.76%). Endoscopy showed a translucent, shiny, pale mass (32 cases) arising from the middle meatus and filling the ipsilateral nasal cavity in all cases, with choanal extension in 29 cases (85.29%) and extension to the nasopharynx in 5 cases (14.70%). CT, performed in all patients, showed opacification of the ipsilateral maxillary sinus in 100% of cases without bone involvement, with ethmoidal involvement in 21 cases (61.76%). All patients underwent endoscopic endonasal middle meatal antrostomy. Histopathology confirmed the diagnosis in all cases. The postoperative course was uneventful, with hospital stay not exceeding two days. After a mean follow-up of 3 years, two recurrences (5.9%; 95% CI: 0.7–19.7) occurred, managed by endoscopic surgery alone in one case and by a combined endoscopic and mini-Caldwell-Luc approach in the other.

Conclusion: ACP is a rare benign tumour of young adults and older children. Diagnosis relies on nasal endoscopy and CT. Endoscopic endonasal middle meatal antrostomy with complete removal of the antral component and of the site of implantation is the reference treatment and limits the risk of recurrence.

Keywords: Antrochoanal Polyp; Killian Polyp; Maxillary Sinus; Endonasal Endoscopy; Middle Meatal Antrostomy; Recurrence.

1 INTRODUCTION

The antrochoanal polyp (ACP), or Killian polyp, is a benign unilateral naso-sinusoidal tumour arising from the mucosa of the maxillary sinus. It protrudes through the maxillary ostium before extending into the ipsilateral nasal cavity and then towards the choana and the nasopharynx, which accounts for its obstructive symptoms [1]. First described by Killian in 1906 [1], it represents approximately 4 to 6% of all nasal polyps [2,3]. Its pathophysiology remains only partially elucidated, and several hypotheses have been put forward: a chronic inflammatory mechanism originating in the antrum, an infectious or allergic mechanism, an abnormality or oedema of the maxillary ostium favouring strangulation and growth of the polyp, a congenital abnormality of sinus development, and more recently lymphatic obstruction [4,6,7,8,9].

Clinical presentation is dominated by unilateral, progressive nasal obstruction that is often well tolerated, which explains the frequent delay in consultation. Positive diagnosis relies on endoscopic examination of the nasal cavities and on computed tomography (CT) of the facial skeleton, which specify the site, the extent and the anatomy of the middle meatus. Magnetic resonance imaging (MRI) retains a role in atypical forms. Definitive diagnosis is histopathological [4,5].

Therapeutically, the advent of endoscopic endonasal surgery has profoundly changed management and has replaced classical approaches, in particular the Caldwell-Luc technique. The quality of excision of the antral component and of the site of implantation largely determines the risk of recurrence [17,18,19].

2 MATERIAL AND METHODS

This was a retrospective, descriptive, single-centre study conducted in the Department of Otorhinolaryngology and Head and Neck Surgery of the Avicenne Military Hospital of Marrakech, over a five-year period, from January 2010 to December 2025.

Population and data source. The exhaustive list of patients hospitalised for the management of an ACP was established from the department register. All patients underwent history-taking, a complete ENT examination, paraclinical investigations including radiology, surgical treatment and systematic histopathological examination.

Inclusion criteria. Patients operated on for an ACP between 2015 and 2020 were included, whose epidemiological and clinical data as well as functional and anatomical results could be evaluated.

Exclusion criteria. Patients who refused surgery were excluded, as were patients lost to follow-up postoperatively with no possibility of evaluating therapeutic results.

Surgical procedure. All patients were operated on under general anaesthesia with orotracheal intubation, after a pre-anaesthetic consultation and collection of informed consent. Prior local anaesthesia combined the placement of hydrophilic cotton pledgets soaked in 5% naphazoline xylocaine in both nasal cavities for 15 minutes. The patient was placed in the supine position, the head slightly turned towards the operated side, on a table in a head-up (reverse Trendelenburg) position, under a surgical drape exposing the eyes and the nasal cavities. The surgical procedure consisted of a middle meatal antrostomy via an endoscopic endonasal approach, with extraction of the intrasinusoidal component, delivery of the polyp through the ipsilateral nostril or exteriorisation into the nasopharynx for recovery through the mouth, followed by coagulation of the implantation pedicle. Haemostasis was systematically verified, with possible coagulation using bipolar forceps.

Postoperative care and follow-up. Nasal packing was left in place for 24 to 48 hours under antibiotic cover, combined with analgesia. After removal of the packing, several-times-daily irrigation of the nasal cavities with physiological saline was prescribed for four weeks, combined with local corticosteroid therapy, with weekly endoscopic monitoring for the removal of crusts. Follow-up comprised a postoperative consultation at one month, at six months and then annually, The mean follow-up was 3 years.

3 RESULTS

3.1 Epidemiology

Age and sex. The mean age of the patients was 35.4 years (range: 12–82 years), with a peak frequency between 30 and 40 years; more than 65% of patients were under 40 years (Figure 1). The series comprised 22 men (64.7%) and 12 women (35.3%), giving a sex ratio of 1.83 (Figure 2).

History. As regards general history, 7 patients (20.58%) had diabetes, 5 (14.70%) arterial hypertension and 2 (6%) treated pleuropulmonary tuberculosis. Nine patients (26.47%) had a history of allergic rhinitis; 25 patients had no particular pathological history, notably no asthma, no aspirin intolerance and no rhino-sinusoidal disease. No history of naso-sinusoidal surgery, and no family history of rhino-sinusoidal disease, was found.

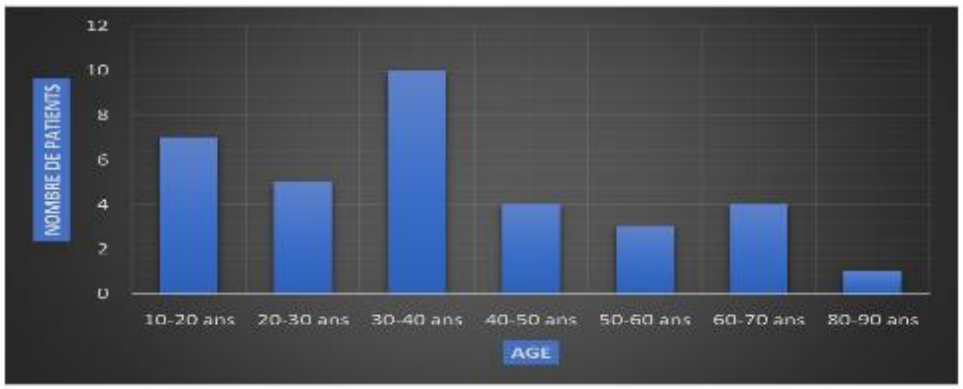

Figure 1: Age of the patients: observed range (12–82 years), mean (35.4 years) and peak frequency (30–40 years) (chart labels in French: "Nombre de patients" = number of patients, "Âge" = age).

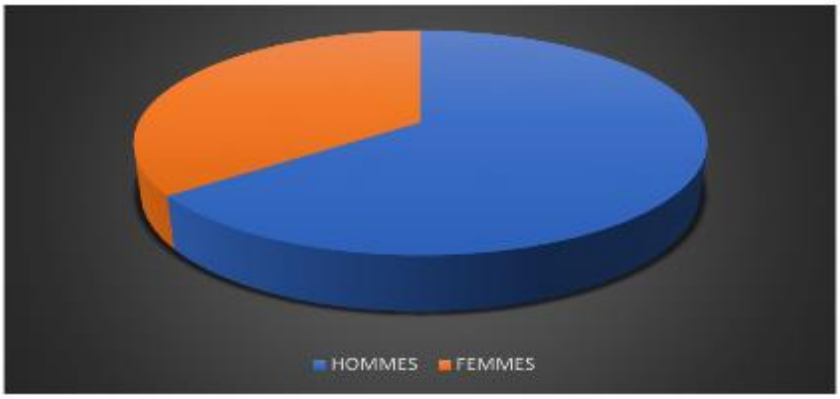

Figure 2: Distribution of patients by sex (n = 34; sex ratio 1.83). Blue sector: men; orange sector: women (the original chart carries no figures on the sectors).

3.2 Clinical study

The time before the first consultation ranged from 1 month to 30 years, with a mean of 3.91 years (Figure 3).

The functional symptoms were as follows (Figure 4):

- Nasal obstruction: 34 cases (100%) — unilateral right in 19 cases (55.88%), unilateral left in 13 cases (38.23%) and bilateral in 2 cases (5.88%).
- Rhinorrhoea: 26 cases (76.47%) — purulent in 10 cases (29.41%), clear in 16 cases (47.05%).
- Headache: 5 cases (14.70%).
- Epistaxis: 3 cases (8.82%).
- Nocturnal snoring: 4 cases (11.76%).
- No patient presented with anosmia, dyspnoea, dysphagia or obstructive sleep apnoea syndrome.

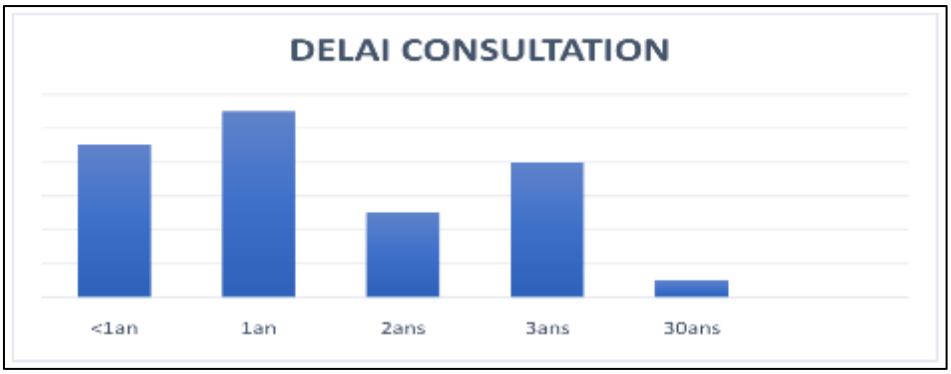

Figure 3: Time to consultation, from 1 month to 30 years, mean 3.91 years (original French title: "Délai consultation")

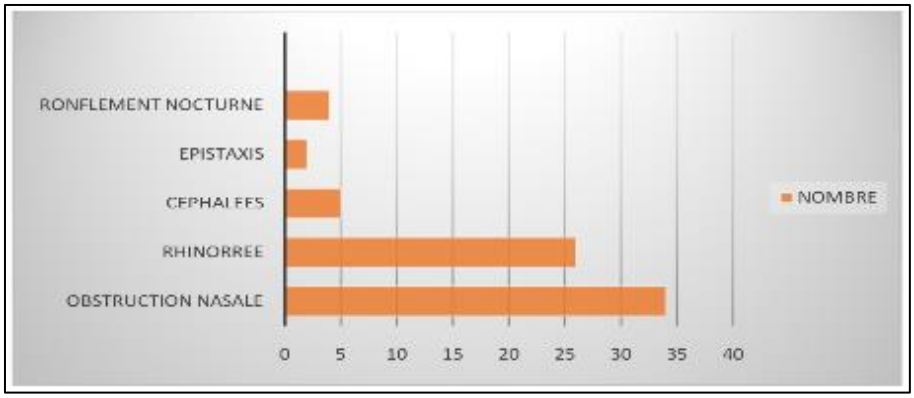

Figure 4: Distribution of the functional signs revealing the antrochoanal polyp (n = 34). From top to bottom: nocturnal snoring, epistaxis, headache, rhinorrhoea, nasal obstruction.

3.3 Physical and endoscopic examination

The ENT examination was based on anterior and posterior rhinoscopy and on the oral-pharyngeal examination. Endoscopic examination of the nasal cavities, performed in all patients with a 0° and 30° rigid endoscope after local anaesthesia with cotton pledgets soaked in 5% naphazoline xylocaine, made it possible to specify the data presented in Table I.

The appearance of the polyp was translucent, shiny and pale in 32 cases, tissue-like in 1 case and cystic in 1 case; the polyp arose from the middle meatal region in all cases, with filling of the ipsilateral nasal cavity. Extension was choanal in 29 cases (85.29%) and reached the nasopharynx in 5 cases (14.70%). The remainder of the ENT examination and the general physical examination — notably ocular, neurological and respiratory — were unremarkable.

3.4 Paraclinical study

Computed tomography. Preoperative naso-sinusoidal CT was performed in all patients, at high resolution with spiral acquisition and axial and coronal reconstructions, without contrast injection, in bone and parenchymal windows, after nose-blowing and cleaning of the nasal cavities. It demonstrated an isodense image filling the maxillary sinus and protruding through its ostium into the nasal cavity in 100% of cases, with projection into the nasopharynx through the choana in 5 cases (14.70%), without bone involvement (Figures 5 and 6). The CT analysis of the other sinuses was as follow

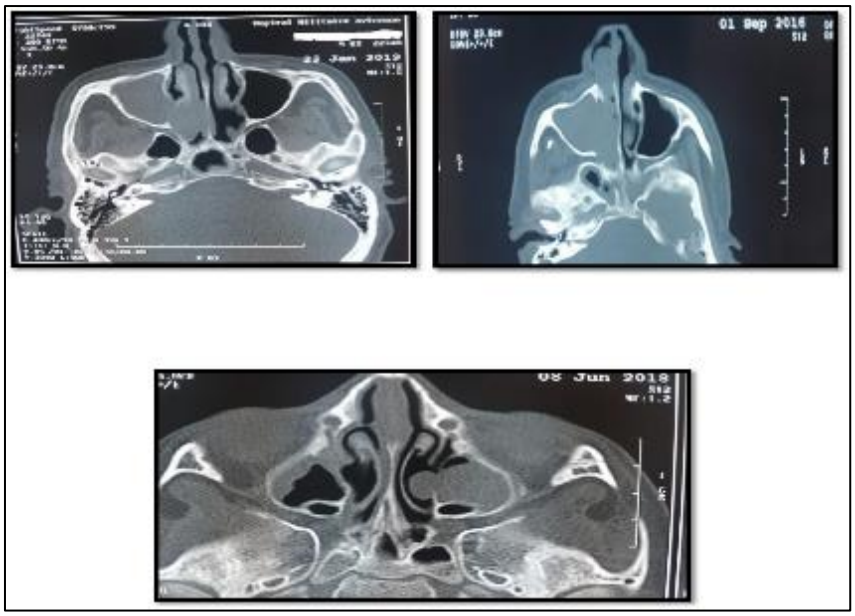

Figure 5: Naso-sinusoidal CT, axial slices: Killian polyp with its two components, sinusoidal and nasal (ENT Department, Avicenne Military Hospital, Marrakech).

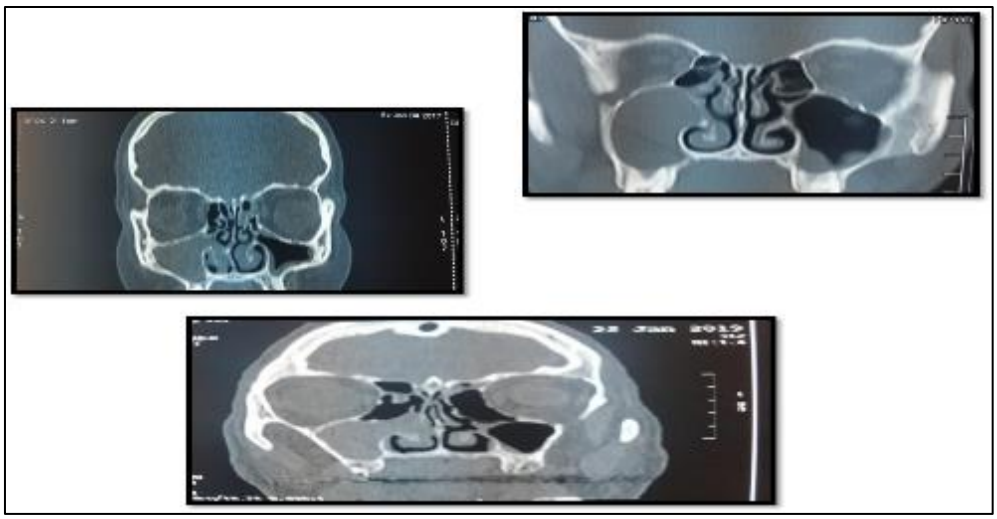

Figure 6: Naso-sinusoidal CT, coronal slices: Killian polyp with its sinusoidal and nasal portions and filling of the right maxillary sinus (ENT Department, Avicenne Military Hospital, Marrakech).

Involvement was unilateral in 32 cases, affecting the right side in 19 cases (55.88%) and the left side in 13 cases (38.23%), and bilateral in 2 cases (5.88%) (Figure 7).

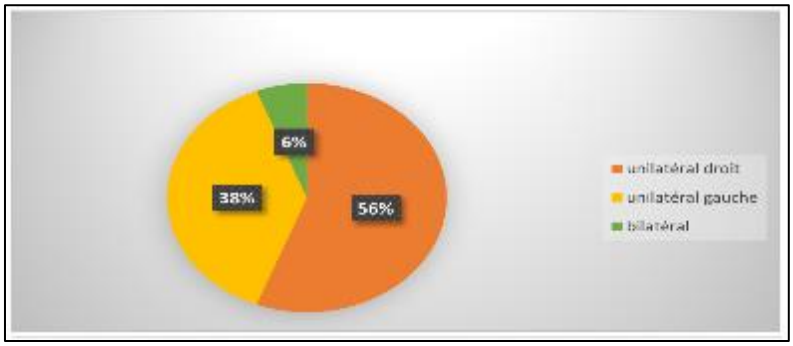

Figure 7: Distribution of patients according to the affected side (n = 34): right 56%, left 38%, bilateral 6%.

Magnetic resonance imaging. No patient required MRI as a complement, given the characteristic appearance of the polyp on CT and the highly suggestive endoscopic appearance.

Pretherapeutic biological work-up. A biological work-up was performed in all patients (blood count, blood grouping, haemostasis work-up, complete serum ionogram). The blood count was normal in all patients, without eosinophilia. No allergy work-up — skin tests or IgE assay — was performed.

3.5 Therapeutic management

All patients were operated on after being informed of the surgical risks and after collection of informed consent, following a pre-anaesthetic consultation. All underwent a middle meatal antrostomy via an endoscopic endonasal approach (Figures 9), according to the technique described above, with coagulation of the implantation pedicle.



Figure 9: Intraoperative view: middle meatal antrostomy (ENT Department, Avicenne Military Hospital, Marrakech).

3.6 Histopathology

Histopathological examination of the surgical specimen was systematic and confirmed the diagnosis of ACP in all cases. Macroscopic study noted a polypoid appearance of the antral portion in 100% of cases (Figure 11). Microscopic study, after haematoxylin-eosin staining, showed respiratory-type, cylindrical and pseudostratified epithelium, a myxoid stroma with inflammatory cells predominantly lymphoplasmacytic and concentrated at the surface, rare eosinophilic infiltrates and rare submucosal glands.

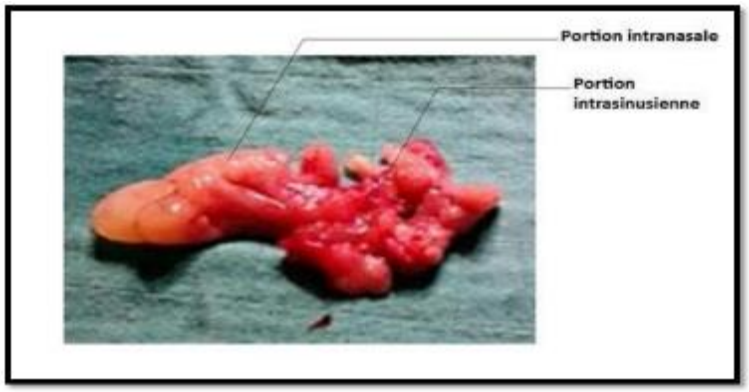

Figure 11: Macroscopic appearance of the Killian polyp, with its two portions, sinusoidal and nasal (ENT Department, Avicenne Military Hospital, Marrakech).

3.7 Postoperative course

The immediate postoperative course was uneventful in all patients, with a hospital stay not exceeding 2 days in all cases. After a mean follow-up of 3 years, two recurrences were observed, i.e. a rate of 5.9% (95% CI: 0.7–19.7), occurring between 1 and 2 years after the first operation

. Surgical revision consisted of a middle meatal antrostomy for the first case and of a combined endoscopic endonasal and mini-Caldwell-Luc approach for the second. Subsequent postoperative endoscopic examinations showed no treatment failure.

4 DISCUSSION

ACP is a rare entity, representing 4 to 6% of all nasal polyps and about 3 to 6% of operated naso-sinusoidal polyps . Our series of 34 cases over five years confirms this rarity while constituting, for a single-centre department, a notable caseload. ACP preferentially affects young adults and older children, with a peak frequency in our series between 30 and 40 years and more than 65% of patients aged under 40. Our mean age of 35.4 years ,is in line with the data of the literature, which report means usually between 20 and 40 years depending on the series and on the respective proportion of adult and paediatric populations . The minimum age of 12 years and the absence of younger paediatric cases in our recruitment are explained by the military nature of the hospital.

The male predominance observed in our series (sex ratio 1.83) is not consistently found in the literature: some series report a male predominance, others a balanced distribution or a slight female predominance . This result must therefore be interpreted with caution and could reflect, at least in part, the particular recruitment of a military hospital.

Nasal endoscopy, together with CT, is the cornerstone of diagnosis. It typically shows a pale, shiny and translucent mass arising from the middle meatus and filling the nasal cavity, sometimes with extension visible to the choana or the nasopharynx, as in 85.29% and 14.70% of our cases respectively. Naso-sinusoidal CT, performed in all our patients, constantly showed filling of the ipsilateral maxillary sinus with protrusion through the ostium, without bone involvement, confirming the benign and non-invasive nature of the lesion and consistent with the classical descriptions of the literature . It is essential in order to specify the sinusoidal extension, to assess anatomical variants (septal deviation in 11.76% of cases, inferior turbinate hypertrophy in 14.70%) and to plan the surgical procedure.

MRI was necessary in none of our patients, given the characteristic appearance of the lesion on CT and at endoscopy. It nevertheless retains a role in atypical forms, where it makes it possible to distinguish ACP from other naso-sinusoidal lesions and to analyse extension to the soft tissues. The absence of a systematic allergy work-up in our series constitutes a limitation, but reflects the management practice of that period.

Treatment of ACP is exclusively surgical. In our series, all patients underwent a middle meatal antrostomy via an endoscopic endonasal approach, with complete excision of the antral component and coagulation of the implantation pedicle. This technique, less invasive than the external Caldwell-Luc approach, offers better visual control of the middle meatus, preserves sinus physiology, reduces morbidity and hospital stay — not exceeding 2 days in our series — and provides direct access to the origin of the polyp . These advantages explain why endoscopic endonasal surgery has become established as the reference treatment, replacing classical procedures

The quality of excision of the antral component and of the implantation pedicle is the main prognostic factor for recurrence. In our series, the recurrence rate was 5.9% (2/34; 95% CI: 0.7–19.7) after a mean follow-up of 3 years, occurring between 1 and 2 years after the operation. This rate is comparable to the data of the literature, which report recurrence rates generally between 0 and 25% depending on the series and the techniques used, the highest rates being observed after incomplete excision of the antral component or when the intrasinusoidal portion is not treated .In the event of recurrence, surgical revision may consist of a new middle meatal antrostomy, an extended endoscopic procedure — notably an enlarged middle meatal antrostomy or resection of the uncinate process — or, in the event of failure or of particular extension, a combined endoscopic and mini-Caldwell-Luc approach, as performed in one of our two patients . Neither of these two revisions was followed by further failure. Topical application of mitomycin C after endoscopic excision has also been proposed in order to reduce the risk of recurrence .

Perspectives. A better understanding of the aetiopathogenesis of ACP — notably through histological, immunohistochemical and molecular studies comparing antral, nasal and choanal mucosa — could pave the way for therapeutic or even preventive advances. From a clinical standpoint, multicentre prospective series with prolonged follow-up and analysis of recurrence factors would make it possible to confirm the value of endoscopic middle meatal antrostomy and to optimise follow-up modalities.

5 CONCLUSION

The antrochoanal polyp, or Killian polyp, is a benign, unilateral and naso-sinusoidal condition arising from the mucosa of the maxillary sinus and extending towards the ipsilateral nasal cavity and then towards the choana and the nasopharynx. Rare — 4 to 6% of all nasal polyps — it preferentially affects young adults and older children, and its pathophysiology remains only partially explained.

A better understanding of the aetiopathogenesis of the Killian polyp would, in the future, allow therapeutic or even preventive advances.

STATEMENTS ON COMPLIANCE WITH ETHICAL STANDARDS

Acknowledgments

Authors sincerely acknowledge and thank all the participants for their valuable time, cooperation, and contributions to this study.

Disclosure of conflict of interest

The authors declare that they have no conflict of interest.

Statement of informed consent

Electronic informed consent was obtained from all individual participants included in the study.

REFERENCES

[1] Killian G. The origin of the choanal polyp. Lancet. 1906;2:81–82.

[2] Larsen K, Tos M. The estimated incidence of symptomatic nasal polyps. Acta Otolaryngol. 2002;122(2):179–182.

[3] Frosini P, Picarella G, de Campora E. Antrochoanal polyp: analysis of 200 cases. Acta Otorhinolaryngol Ital. 2009;29(1):21–26.

[4] Maldonado M, Martinez A, Alobid I, Mullol J. The antrochoanal polyp. Rhinology. 2004;42(4):178–182.

[5] Islas FAE, González JLT, Camarillo JMM. Antrochoanal polyp: a literature update. J Otolaryngol Rhinol. 2018;4:049.

[6] Sunagawa M, Kinjoh K, Nakamura M, Kosugi T. Urokinase-type plasminogen activator and plasminogen activator inhibitor antigen in tissue extracts of paranasal sinus mucous membranes affected by chronic sinusitis and antrochoanal polyps. Eur Arch Otorhinolaryngol. 1999;256(5):237–241.

[7] Jang YJ, Rhee CK, Oh CH, Ryoo HG, Kim HG. Arachidonic acid metabolites in antrochoanal polyp and nasal polyp associated with chronic paranasal sinusitis. Acta Otolaryngol. 2000;120(4):531–534.

[8] Mahfouz ME, Elsheikh MN, Ghoname NF. Molecular profile of the antrochoanal polyp: up-regulation of basic fibroblast growth factor and transforming growth factor beta in maxillary sinus mucosa. Am J Rhinol. 2006;20(4):466–470.

[9] Mostafa HS, Fawzy TO, Jabri WR, Ayad E. Lymphatic obstruction: a novel etiologic factor in the formation of antrochoanal polyps. Ann Otol Rhinol Laryngol. 2014;123(6):381–386.

[10] Pagella F, Emanuelli E, Pusateri A, Borsetto D, Cazzador D, Marangoni R, et al. Clinical features and management of antrochoanal polyps in children: cues from a clinical series of 58 patients. Int J Pediatr Otorhinolaryngol. 2018;114:87–91.

[11] Al-Mazrou K, Bukhari M, Al Fayez A. Characteristics of antrochoanal polyp in the pediatric age group. Ann Thorac Med. 2009;4(3):133–136.

[12] Yaman H, Yilmaz S, Karali E. Evaluation and management of antrochoanal polyps. Clin Exp Otorhinolaryngol. 2010;3(2):110–114.

[13] Porcuna DV, Montserrat Gili JR, Gras Cabrerizo JR, Lopez Vilas M, Olmo AP. Unilateral benign choanal polyp: review of 51 patients. Acta Otorrinolaringol Esp. 2008;59(2):52–56.

[14] Choudhury N, Hariri A, Saleh H. Endoscopic management of antrochoanal polyps: a single UK centre's experience. Eur Arch Otorhinolaryngol. 2015;272(9):2305–2311.