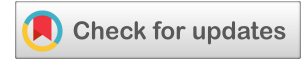



(CASE REPORT)



Benign familial fleck retina: A case report

Shubham Sehgal ^{1,*}, Jayashree S Shah ², Lokesha HM ³ and Niveditha RK ⁴

¹ Department of ophthalmology, Post graduate resident, Sri Siddhartha academy of higher education (SSAHE), TUMKUR, Karnataka, India.

² Department of ophthalmology, HOD and Professor, Sri Siddhartha academy of higher education (SSAHE), TUMKUR, Karnataka, India.

³ Department of ophthalmology, Professor, Sri Siddhartha academy of higher education (SSAHE), TUMKUR, Karnataka, India.

⁴ Department of ophthalmology, Assistant Professor, Sri Siddhartha academy of higher education (SSAHE), TUMKUR, Karnataka, India.

International Journal of Science and Research Archive, 2024, 13(01), 3224–3226

Publication history: Received on 14 September 2024; revised on 24 October 2024; accepted on 26 October 2024

Article DOI: <https://doi.org/10.30574/ijrsra.2024.13.1.2031>

Abstract

This case report presents imaging of a 38-year-old male who was diagnosed with Benign Familial Fleck Retina (BFFR) which is an uncommon disorder. Fundus photographs revealed retinal flecks that affected his post-equatorial retina and spared the macular area. His full-field electroretinogram and electrooculogram were normal. An optical coherence tomography B-scan was performed for both of his eyes, and it revealed increased thickness of the retinal pigmented epithelium. The outer retina was intact in both of his eyes. Benign familial fleck retina belongs to a heterogenous group of flecked retina syndromes, and should be considered in patients with yellowish-white retinal lesions with macular sparing.

Keywords: Benign Familial Fleck Retina; Flecked retina syndromes, Retinal flecks, fovea-sparing hypofluorescent spots

1. Introduction

Benign familial fleck retina (BFFR) is a congenital abnormality which is characterized by multifocal yellowish retinal infiltrates that involve the post-equatorial retina. ^{1,2}

It is a rare condition which has been observed predominantly in children and young adults that present with yellow to white symmetrical flecks bilaterally with otherwise normal acuity, visual fields, and retinal function. ^{3,4}

The flecks are located at the level of the retinal pigment epithelium (RPE), and they extend to the far periphery with sparing of the macula^{5,6}

2. Case report

A 38-year-old male presented to the ophthalmology department for his routine ophthalmic examination. His visual acuity was 20/20 for both eyes, normal color vision and there were no abnormalities detected on slit lamp examination. Fundus photographs in both eyes displayed multiple, small, symmetrical, yellow-white fovea-sparing fleck-like lesions that were spread across the retina, and were arranged concentrically as documented in the fundus photograph.

* Corresponding author: Shubham Sehgal

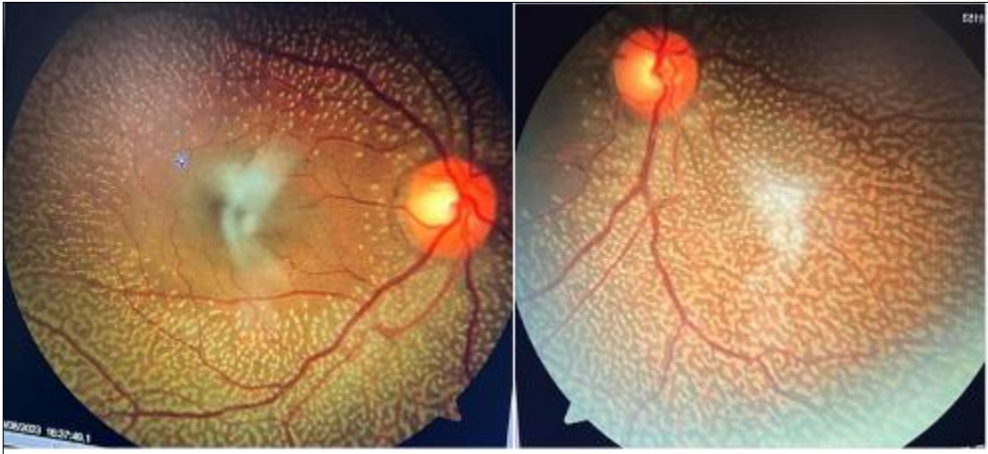

Figure 1 Fundus photographs showing multiple, small, yellow-white fleck like lesions with sparing of the fovea

None of his family members were affected. There was no history of consanguinity in the family.

Fluorescein angiography showed hypofluorescent spots that were related to pigment clumps and were extending to periphery but there was no injury to the macula.

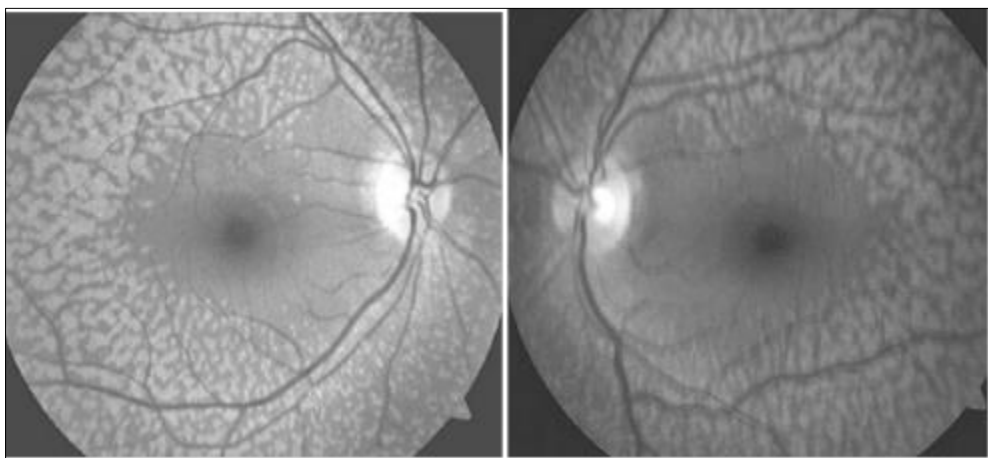


Figure 2 Fluorescein angiography showing hypofluorescent spots extending to periphery with a healthy macula

OCT showed a normal foveal structure with increased thickness of Retinal Pigment Epithelium in both eyes.

Full-field and pattern electroretinogram and electrooculogram in both eyes were normal.

Diagnosis of benign familial fleck retina (BFFR) was made.

3. Discussion

When compared to previous cases of BFFR, this case has some common features with them such as normal color vision, visual acuity. Given the normal ocular findings in his family there is evidence supporting an autosomal recessive pattern of inheritance consistent with BFFR.

Since the original description of a family with benign fleck retina, only three sporadic cases have been reported^(2,6).

Some authors have postulated that flecks do not only represent a typical ophthalmic characteristic but may also correspond to retinal damage that contributes to loss of vision⁽⁷⁾. It has been suggested that the flecks may be related to *PLA2G5* mutations^(8,9).

4. Conclusion

Routine ophthalmic examination should be done thoroughly to detect conditions like BFFR in patients having no visual symptoms. This case report is significant as it is important to differentiate BFFR from disorders like fundus albipunctatus, familial drusen, retinitis puncta albescens, etc to educate the patient about the prognosis of their vision.

Compliance with Ethical Standards

Disclosure of conflict of interest

There were no conflicts of interest.

Statement of ethical approval

All procedures in this case report were in accordance with the ethical standards of *Sri Siddhartha academy of higher education*. This report does not contain any studies with animals performed by any of the authors.

Statement of informed consent

Written informed consent was obtained from the patient to publish this case report in accordance with the journal's patient consent policy.

References

- [1] Aish SF, Dajani B. Benign familial fleck retina. *Br J Ophthalmol*. 1980;64(9):652-59
- [2] Isaacs TW, McAllister IL, Wade MS. Benign fleck retina. *Br J Ophthalmol*. 1996;80(3): 267-8.
- [3] Sabel Aish SF, Dajani B. Benign familial fleck retina. *Br J Ophthalmol*. 1980;64(9):652-659. doi: 10.1136/bjo.64.9.652
- [4] Isaacs TW, McAllister IL, Wade MS. Benign fleck retina. *Br J Ophthalmol*. 1996;80(3):267-268
- [5] Audo I, Tsang SH, Fu AD, Barnes JA, Holder GE, Moore AT. Autofluorescence imaging in a case of benign familial fleck retina. *Arch Ophthalmol*. 2007;125(5):714-5.
- [6] Galindo-Ferreiro A, Sanabria MR, Garcia EP, Coco-Martin RM, Galindo-Alonso J, Palencia-Ercilla J. Benign fleck retinal findings on multifocal ERG, microperimetry, and OCT. *Ophthalmic Surg Lasers Imaging*. 2010 Oct 28;41 Online:e1-5. doi: 10.3928/15428877-20101025-05.
- [7] Verdina T, Tsang SH, Greenstein VC, Zernant J, Sodi A, Lima LH, et al. Functional Analysis of Retinal Flecks in Stargardt Disease. *J Clin Exp Ophthalmol*. 2012 Jul 30;3. doi: 10.4172/2155-9570.1000233.
- [8] Sergouniotis PI, Davidson AE, Mackay DS, Lenassi E, Li Z, Robson AG, Yang X, et al. Biallelic mutations in PLA2G5, encoding group V phospholipase A2, cause benign fleck retina. *Am J Hum Genet*. 2011;89(6):782-91.
- [9] Bin NJ, Heng HM, Poh R, Noor SM, Subrayan V. Phospholipase A2 group v in benign familial fleck retina in a set of triplets. *Retina*. 2015;35(6):1266-72.