

## Ocular manifestations in neurofibromatosis: A case series

Nikita Nijhawan <sup>1,\*</sup>, Jayashree S Shah <sup>2</sup>, Niveditha RK <sup>3</sup> and Lokesha HM <sup>4</sup>

<sup>1</sup> Postgraduate Department of Ophthalmology, Sri Siddhartha Medical College and Research Centre, Tumkur, Sri Siddhartha Academy of Higher Education, Tumkur, Karnataka, India.

<sup>2</sup> Professor and Head Department of Ophthalmology, Sri Siddhartha Medical College and Research Centre, Tumkur, Sri Siddhartha Academy of Higher Education, Tumkur, Karnataka, India.

<sup>3</sup> Assistant professor, Department of Ophthalmology, Sri Siddhartha Medical College and Research Centre, Tumkur, Sri Siddhartha Academy of Higher Education, Tumkur, Karnataka, India.

<sup>4</sup> Professor, Sri Siddhartha Medical College and Research Centre, Tumkur, Sri Siddhartha Academy of Higher Education, Tumkur, Karnataka, India.

International Journal of Science and Research Archive, 2024, 13(01), 2994–3000

Publication history: Received on 11 September 2024 ; revised on 20 October 2024; accepted on 22 October 2024

Article DOI: <https://doi.org/10.30574/ijrsra.2024.13.1.2008>

### Abstract

**Background:** A collection of inherited diseases known as neurofibromatosis (NF) are distinguished by a broad spectrum of clinical manifestations. A genetic mutation on chromosome 17 (17q11.2) is the cause of NF type 1 (NF1), whereas a mutation on chromosome 22 (22q12.2) is the cause of NF type 2 (NF2). In NF1, ocular symptoms are more frequent. Patients with NF1 commonly appear with globe enlargement, glaucoma, and orbital facial involvement. Palpebral neurofibromas have the potential to grow extensively and, in rare instances, develop into malignant tumors. Optic nerve gliomas can result in strabismus and proptosis. Up to 80% of patients with NF2 may experience early-onset cataracts, optic nerve hamartomas, and mixed pigment retinal and epithelial hamartomas.

**Case presentation:** We present four cases of neurofibromatosis, each displaying typical clinical features of the disorder.

- Case 1: A 28-year-old male presented with headaches, reduced vision, and multiple tiny discolorations in both eyes for six months. Examination revealed multiple hyperpigmented skin lesions (2-5 mm) across his body, and ocular assessment showed normal pupillary reactions and distant vision of 6/6 in both eyes. Slit-lamp examination identified multiple dome-shaped lesions on the iris, consistent with Lisch nodules.
- Case 2: A 42-year-old female experienced reduced vision for six months and skin lesions for five years. Examination revealed multiple discrete skin-colored papules and café-au-lait macules on her hands. Her vision was 6/12 in both eyes, with normal pupillary reactions. Slit-lamp findings were also consistent with Lisch nodules.
- Case 3: A 48-year-old male reported vision loss in both eyes over two months, accompanied by swelling of the right upper eyelid, which was increasing in size. Lisch nodules were found on the iris of the left eye, and he was diagnosed with typical NF.
- Case 4: A 38-year-old male presented with diminished vision. Slit-lamp examination revealed multiple dome-shaped lesions on the iris, suggesting Lisch nodules, along with skin lesions on the face and other body areas

**Conclusion:** Managing neurofibromatosis requires a multidisciplinary approach, involving close collaboration between healthcare providers. Monitoring visual prognosis, enrolling patients in clinical trials, and regular disease monitoring are essential steps in managing the condition.

**Keywords:** Neurofibromatosis; Lisch nodules; Café-au-lait macules; Chromosome 17 [17q 11.2]; Chromosome 22 [22q 12.2]

\* Corresponding author: Nikita Nijhawan

## 1. Introduction

Sturge-Weber syndrome, tuberous sclerosis, von Hippel-Lindau disease, and neurofibromatosis (NF) are a few multisystem genetic illnesses. Ocular involvement and adnexal involvement are regarded as NF's diagnostic characteristics. NF was originally divided into seven varieties by Riccardi; however, the current classification only acknowledges NF1 and NF2, with other variants being regarded as less prevalent. A genetic mutation on chromosome 17 (17q11.2) is the cause of NF1, whereas a mutation on chromosome 22 (22q12.2) causes NF2. NF1 is the most prevalent variety, with a frequency of 1 in 3,500 live births, and is normally inherited in an autosomal dominant pattern, while around 50% of instances come from spontaneous mutations. Clinical diagnosis is frequently made using predetermined standards.<sup>[1]</sup> The most common of the various conditions referred to as hamartomas is NF-1. Most serious ophthalmic manifestation of NF-1 is visual loss secondary to optic nerve glioma.<sup>[2]</sup> To summarise, NF-1 exposes a characteristic cutaneous phenotype that includes benign neurofibromas, which are found in peripheral nerves, hyperpigmented macules called café-au-lait macules, the so-called inguinal/axillary freckling, and pigmented hamartomas in the iris known as Lisch nodules. NF2 is primarily seen in tumours of the central and peripheral nerve systems, which are hardly ever associated with skin conditions.<sup>[3]</sup>

### 1.1. NF1 Clinical Features

NF1 affects 1 in 3,500 individuals, making it one of the most common genetic disorders. Diagnostic criteria for NF1 and NF2 were updated by Guttman in 1997. NF1 typically presents with cutaneous manifestations, with café-au-lait macules (CALMs) being common in childhood.<sup>[3]</sup> CALMs range from 10 to 40 mm in diameter, with a characteristic ovoid shape and light brown color. Inguinal or axillary freckling develops in 90% of patients, often following CALMs. Neurofibromas, either subcutaneous or dermal, may develop on peripheral nerves, with plexiform neurofibromas having a 10% risk of malignant transformation. Lisch nodules, pigmented hamartomas of the iris, are a hallmark of NF1.<sup>[3]</sup> Nerve dysfunction and deformity is caused by plexiform neurofibromas due to their ability to develop along vast portions of afflicted nerves. In NF1, Lisch nodules are pigmented hamartomas of iris which is an important trait.<sup>[3]</sup>

### 1.2. NF2 Clinical Features

NF2, with an incidence of 1 in 25,000, was initially thought to be a subtype of NF1. However, it is now recognized as a distinct condition. Hearing loss is often the first clinical sign of NF2, typically caused by vestibular schwannomas on the auditory nerves. Tumors in NF2 are benign but can cause significant nerve dysfunction. Dermal schwannomas are rare in NF2, and histopathological analysis may be required to differentiate them from neurofibromas. NF2 diagnosis follows the NIH consensus criteria, which require a positive family history or the presence of vestibular schwannomas, meningiomas, gliomas, or other specific features.<sup>[3]</sup>

**Table 1** Clinical Signs of NF Patients

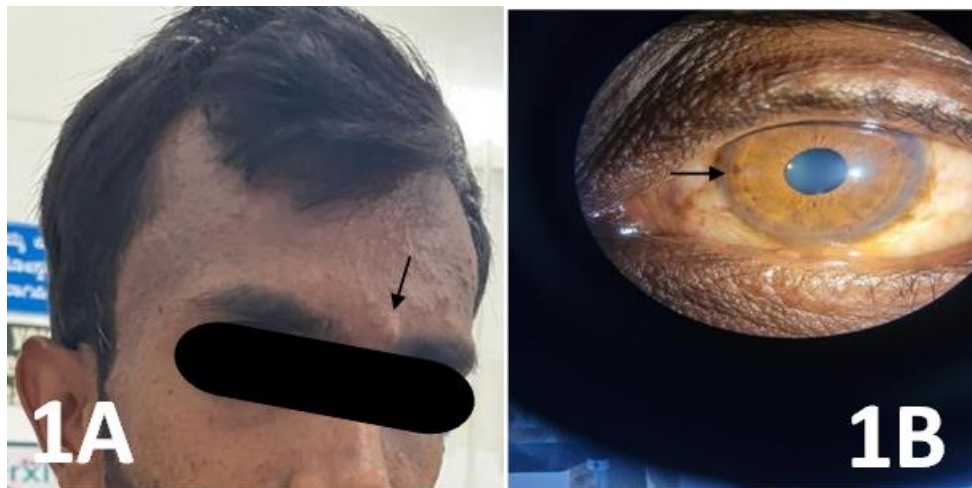| NF type 1               | NF type 2   |
|-------------------------|---|
| Choroid hamartomas      | Spinal and cerebral tumors usually ependymomas or meningiomas |
| Optic nerve gliomas     | Early onset cataracts   |
| Lisch nodules           | Seizures  |
| Retinal tumors          | Bilateral vestibular acoustic neuromas                        |
| Plexiform neurofibromas |   |

**Table 2** Criteria's for diagnosis of NF type 1 and NF type 2

| S.No | NF Type 1  | NF Type 2   |
|------|--|---|
|      |  | Must have $\geq 2$ of the following below   |
| 1.   | 1 plexiform neurofibroma or $\geq 2$ neurofibromas of any type   | A first degree relative with NF2 and unilateral vestibular schwannoma before age 70   |
| 2.   | $\geq 6$ Café au lait macules $>15$ mm in post pubertal individuals $>5$ mm in diameter if prepubertal                   | Before age 70 bilateral vestibular schwannoma   |
| 3.   | Freckling in the inguinal or axillary region   | Any 2 of the following – Neurofibroma, Meningioma, Glioma, Nonvestibular Schwannoma, Cerebral Calcification, Cataract And Either; (1) Unilateral Vestibular Schwannoma And Negative LZTR1 Testing or (2) 1st Degree Relative W/ NF2 |
| 4.   | Optic glioma   | Multiple meningiomas and (1) Any 2 of the following – Meningioma, Cataract, Nonvestibular Schwannoma, Glioma, Neurofibroma, Cerebral Calcification, or(2) Unilateral Vestibular Schwannoma  |
| 5.   | $\geq 2$ Lisch nodules   | Mosaic or constitutional pathogenic NF2 mutation in the same individual from blood or by identification of an identical mutation from 2 separate tumors   |
| 6.   | Distinctive osseous lesion (thinning of long bone cortex, sphenoid wing dysplasia, ,etc) with or without pseudoarthrosis |   |
| 7.   | Based on above, first-degree relative with NF1   |   |

## 2. Case presentation

### 2.1. CASE 1



**Figure 1A** A single neurofibroma present over the glabella, figure **1B** Slit lamp examination showed multiple domed elevated lesions on iris suggestive of Lisch nodules

A case of A 28year old male patient presented with headache and diminution of vision. On general examination multiple hyperpigmented skin lesions of more than 2-5mm in size were presented all over the body.

On Ophthalmic examination: Visual acuity was 6/6, Colour vision was found to be normal. On slit lamp examination: Anterior chamber appears to be normal in depth and content. On iris multiple domed elevated lesions present which are suggestive of Lisch nodules. Pupils of both eyes were round, regular and reactive. Fundus: appears to be normal

### 2.1.1. Investigations

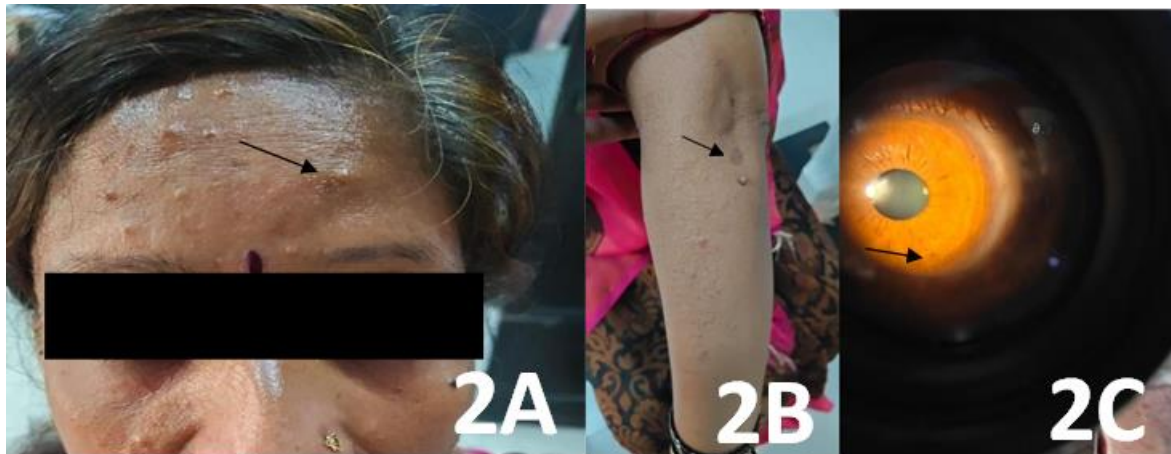IOP-14mmHg in both eyes

MRI brain was advised to rule out any neurological lesions

## 2.2. CASE 2

A case of 42 year old female patient with diminution of vision since 6 months and lesions over full body which the patient noticed 5 years back. On examination multiple discrete skin coloured papules present over full body and café au lait macules present over arm and hand.

On ocular examination distant vision 6/12 both eyes. Colour vision was found to be normal. Slit lamp examination showed multiple domed elevated lesions on iris suggestive of Lisch nodules present on both eyes which is well known diagnostic criteria for the disease.



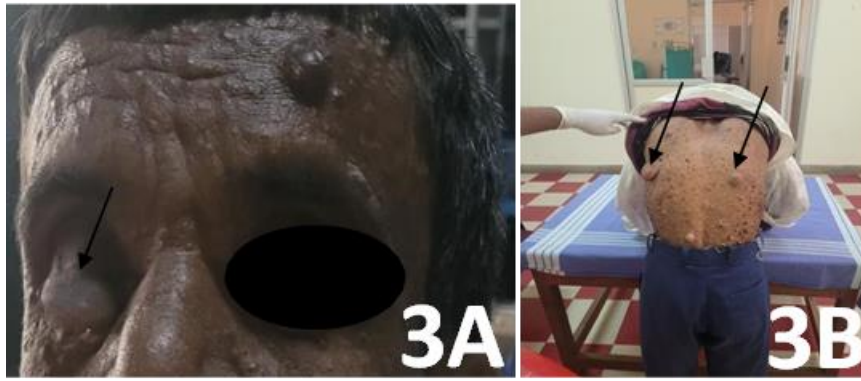**Figure 2A** Multiple neurofibromas present over the forehead; **Figure 2B** Café au lait macules present over arm and hand, **Figure 2C** Lisch nodules present on iris

### 2.2.1. Investigations

Fundus examination: appears to be normal

## 2.3. CASE 3

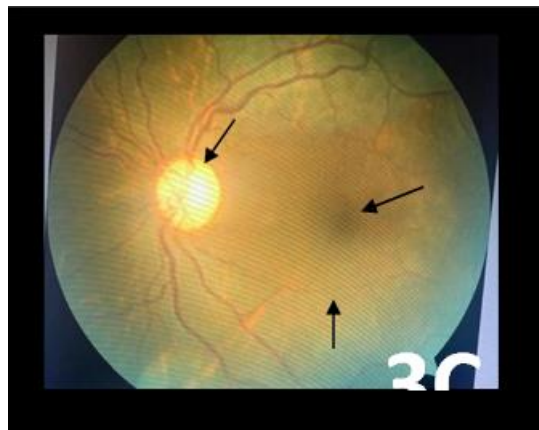
A case of 48 year old male patient presented to ophthalmology OPD with diminution of vision in both eyes since 2 months and swelling of right upper eyelid which was present since childhood gradually increasing in size. Slit lamp examination shows neurofibromas of upper eyelid and total mechanical ptosis of right eye which on forceful opening shows mature cataract. On examination multiple skin lesions were presented all over the body.



**Figure 3A** Neurofibroma of the upper eyelid with total ptosis of right eye, Figure 3B shows multiple neurofibromas over the back along with buttonhole sign which is also present suggestive of neurofibromatosis

### 2.3.1. Investigations

On Ophthalmic examination of both eyes: Visual acuity of Right eye is PL positive, PR accurate and of Left eye is 6/36. Pupils of both eyes are round, regular and reactive.

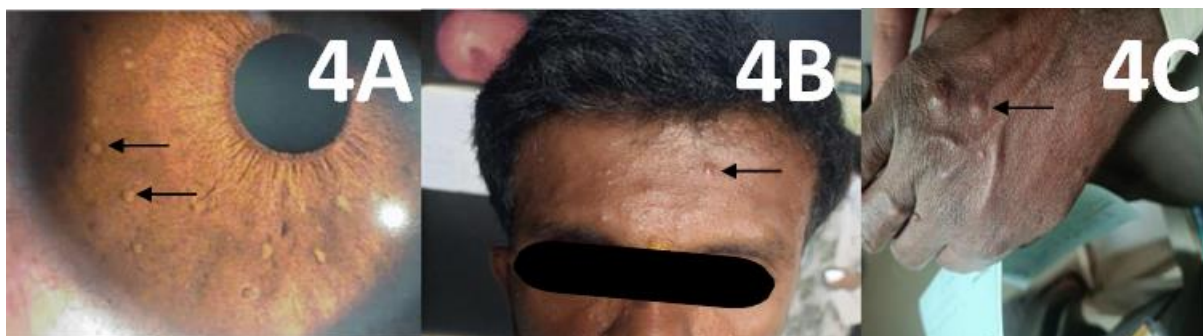


**Figure 3C** On fundus examination, right eye couldn't be visualized due to hazy media. Left eye shows a pale optic disc, attenuated arterioles and pigmentary changes present in macula (Zeiss fundus camera).

### 2.3.2. Investigations

MRI brain was advised to rule out any neurological lesions

## 2.4. CASE 4



**Figure 4A** Multiple domed elevated lesions on iris suggestive of lisch nodules, Figure 4B Multiple skin coloured nodules present over the forehead suggestive of neurofibromas, Figure 4C Skin coloured nodules present over hand

A 38 year old male patient arrived at Ophthalmology OPD with concerns about diminished vision and slit lamp examination showed multiple domed elevated lesions on iris suggestive of Lisch nodules with lesions present over the face and other parts of the body which patient noticed 8 years back.

#### 2.4.1. Investigations

On Ophthalmic examination: Visual Acuity in right eye was 6/6 and left eye was 6/12, With no pin hole improvement in left eye. Colour vision was found to be normal. Anterior segment appears to be normal in depth and content. Pupils of both eyes were round, regular and reactive.

On fundus examination, appears to be normal limits both eyes

---

### 3. Discussion

Von Recklinghausen initially described neurofibromatosis in 1882. An autosomal-dominant condition known as NF1 affects roughly 1 in 2,500–3,500 people globally. Characteristics include sphenoid dysplasia, neurofibromas, café-au-lait spots, iris Lisch nodules, inguinal or axillary freckling, and optic nerve gliomas<sup>[4]</sup> Almost all individuals with NF1 have Lisch nodules, which are the most prevalent ocular symptom of the disorder and first appear in early childhood. In patients with NF1, freckles and café-au-lait spots are common observations. About 80% of patients under 6 years old and 90% of people over 30 have freckles on their skin.<sup>[4]</sup>

Three forms of neurofibromas are commonly identified in NF1 patients: plexiform, cutaneous, and subcutaneous. While subcutaneous neurofibromas are larger (3–4 cm) and typically sensitive to the touch, cutaneous neurofibromas are typically non-tender, measuring only a few millimeters. These neurofibroma forms are not NF1-specific.<sup>[5]</sup> Six or more café-au-lait macules larger than 5 mm in diameter in prepubertal individuals, two or more neurofibromas or one plexiform neurofibroma, freckling in the axillary or inguinal regions, optic glioma, Lisch nodules in the iris, and a first-degree relative with NF1 are the seven criteria that must be present for a diagnosis of NF1.<sup>[6]</sup>

Genetic aspects of NF2 are recorded in a severity score, which correlates with clinical symptoms. The mosaic form includes patients with genetic abnormalities detectable in just particular organs, while the classic form involves mutations discovered in blood cells and often exhibits milder clinical manifestations. Aggressive phenotypes are caused by particular truncating mutations in severe forms. Factors such as age of onset, mutation type, and the frequency of intracranial tumors are key predictors of death in NF2, with missense mutations being associated with a lower mortality risk. About 90% of individuals with NF2 have vestibular schwannomas, which impact the eighth cranial nerve, as their most common presenting symptom. Spinal tumors are detected in a comparable percentage of patients. Meningiomas are identified in roughly 50% of NF2 patients.<sup>[7]</sup>

#### Abbreviations

NF: Neurofibromatosis; NF1: Neurofibromatosis type 1; NF2: Neurofibromatosis type 2; MRI: magnetic resonance imaging; OPD- Out Patient Department

---

### 4. Conclusion

To summarize, there are several ocular symptoms of NF1, the most prevalent of which are Lisch nodules. Since NF1 is an autosomal-dominant genetic condition, issues that could endanger vision can be avoided with early diagnosis. The key to managing NF1 is identifying the characteristic clinical indications and making sure that specialists are referred as soon as possible. For NF1 patients and their families, primary care physicians and family physicians are essential in providing continuing treatment and counseling. Healthcare professionals must work together in a multidisciplinary manner to manage neurofibromatosis. In order to enhance patient care, visual prognosis, routine monitoring, and clinical trial participation are crucial stages.

---

## Compliance with ethical standards

### *Acknowledgments*

This work is dedicated to our faculty members.

### *Disclosure of conflict of interest*

The authors declare that there is no competing interest.

### *Statement of informed consent*

Informed consent was obtained from all individual participants included in the study.

---

## References

- [1] Abdolrahimzadeh B, Piraino DC, Albanese G, Cruciani F, Rahimi S. Neurofibromatosis: an update of ophthalmic characteristics and applications of optical coherence tomography. *Clin Ophthalmol*. 2016;10:851–60. doi: 10.2147/OPTH.S102830.
- [2] Medscape. Neurofibromatosis: Ophthalmologic manifestations of neurofibromatosis Type 1 (NF- 1) Reddy S, Collins F. Neurofibromatosis [Internet]. Medscape; 2023 [cited 2024 Aug 10]. Available from: <https://emedicine.medscape.com/article/1219222-overview#a1>.
- [3] Abolhasani M, Karimzadeh F, Shahidi S, Hosseini S, Mahmoudzadeh B, Karimi F, et al. Neurofibromatosis type 1 with multiple cutaneous lesions. *J Rare Dis Res Treat*. 2022;14(3):102. doi: 10.1186/2047-783X-14-3-102.
- [4] Aldhafeeri M, Baobaid A, Mohammed A, Hussain K. Neurofibromatosis 1: a family case series. *J Family Med Prim Care* [Internet]. 2022 [cited 2024 Aug 10];11(5):111. Available from: [https://pdfs.journals.lww.com/jfmpc/2022/05000/neurofibromatosis\\_1\\_a\\_family\\_case\\_series.111.pdf](https://pdfs.journals.lww.com/jfmpc/2022/05000/neurofibromatosis_1_a_family_case_series.111.pdf).
- [5] Sarkar C, Ghosh D, Chatterjee U. Neurofibromatosis and its effect on oral cavity: An insight into the disease. *J Oral Maxillofac Pathol* [Internet]. 2021 [cited 2024 Aug 10];25(3):541–7. Available from: <https://www.ncbi.nlm.nih.gov/pmc/articles/PMC8494155/>.
- [6] Verma S, Singh P, Kharbanda S, Jindal A. Neurofibromatosis type 1: A review of the literature. *J Clin Diagn Res* [Internet]. 2016 [cited 2024 Aug 10];10(6)–5. Available from: [https://jcdr.net/articles/PDF/8780/21041\\_CE%5BRa%5D\\_F%28P%29\\_PF1%28AH\\_OM%29\\_PFA%28AK%29\\_PF2%28PAG%29.pdf](https://jcdr.net/articles/PDF/8780/21041_CE%5BRa%5D_F%28P%29_PF1%28AH_OM%29_PFA%28AK%29_PF2%28PAG%29.pdf).
- [7] Li Q, Wei Q, Fu Y, Wang S, Wang Y, Zhang Y. Association of NF1 gene mutations with clinical features in neurofibromatosis type 1 patients. *Appl Sci* [Internet]. 2023 [cited 2024 Aug 10];13(10):6304. Available from: <https://www.mdpi.com/2076-3417/13/10/6304>.